Jurnal Medical Aradean (Arad Medical Journal)
Vol. XVIII, issue 2, 2015, pp. 60-63
© 2015 Vasile Goldis University Press (www.jmedar.ro)

HER-2 / neu Expression in assesment of the oncogene risk of ulcerative colitis

Florinel Cozma[1], Marius Raica[2], Carmen Neamtu[1], Totolici Bogdan[1]
1 Western University "Vasile Goldis" Arad
2 University of Medicine and Pharmacy Timişoara

ABSTRACT. Human HER-2 gene encodes a protein that is a membrane receptor for epidermal growth factor. Most studies on the HER-2 had bladder cancer and breast object. We have questioned whether overexpression of HER-2 / neu may be observed in patients with UC, and found that this protein has individual prognostic value at pacients with active UC.
KEYWORDS: colitis, bladder cancer, HER-2, breast object, malignant tumors

INTRODUCTION

UC is an idiopathic disorder of the intestine, located in the large intestine and rectum with chronic evolution that alternates with phases of variable severity with remission. One of the controversial issues regarding its condition is represented by the risk of malignancy.

MATERIAL AND METHOD

In a prospective study conducted at the gastroenterology clinic of the Emergency Hospital Arad were analyzed 42 patients with ulcerative colitis, from which were taken both biopsies in the form of evident lining of macroscopic lesions and the lining apparently healthy overlying the lesion. Also included in the study were biopsies and rectal adenocarcinomas 4 to 6 normal rectal biopsies.

In the immunohistochemistry to determine the expression of HER-2 / neu, homologous epidermal growth factor receptor.

Visualization Systems

Human HER-2 gene (also known as ErbB2 and NEU) encodes a protein known as HER-2 or p185. HER-2 protein is a membrane recptor tyrosine kinase, homologous to the epidermal growth factor receptor (EGFR or HER-1). HER-2 protein is a coimponent normally expressed by a variety of epithelial cells. Most studies on the HER-2 were dealt breast and bladder cancer, the overexpression part of the process of malignant transformation and progression. Overexpression of HER-2 protein on the surface of malignant cells suggests that it may be used as a target for anti-cancer therapy structure based on synthetic antibodies. Herceptin (transtuzumab) is a humanized monoclonal antibody that has high affinity for the HER-2 protein. Herceptin has been shown to inhibit human tumor cell proliferation, in the case where there is overexpression of HER-2 protein. We put natural question: overexpression of HER-2 / neu may be observed in patients with ulcerative colitis? In all or only in some cases? It does predict the eventual transformation of injuries in adenocarcinoma?

In order to answer at least two of intrtebarile above, in all cases included sections were stained with DAKO instudiu Hercep Test after prior exposure to microwave antigen in the solution of citrate buffer pH 6 for 40 minutes. View the final reaction product was performed with diaminobenzidine.

Overexpression of HER2 score table

Coloring Pattern	Score	Overexpression of HER2
No membrane staining or coloring to more than 10% tumor cells	0	Negative
Staining weak but perceptible over 10% of the cells; discontinuous membrane distribution	+1	Negative
Weak or moderate membrane staining continues to over 10% of the tumor cells	+2	Less intense positive
Intense membrane staining, continuing more than 10% of tumor cells	+3	Intense positive

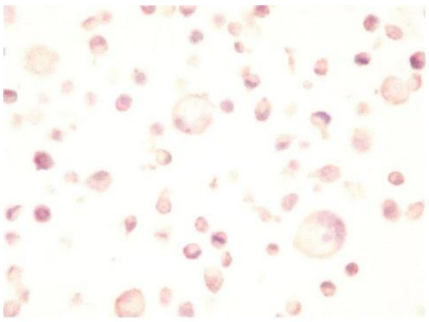

Figure 1. Negative

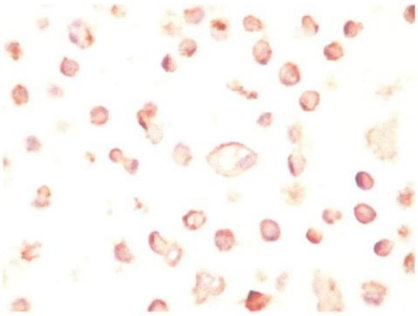

Figure 2. Pozitiv +1

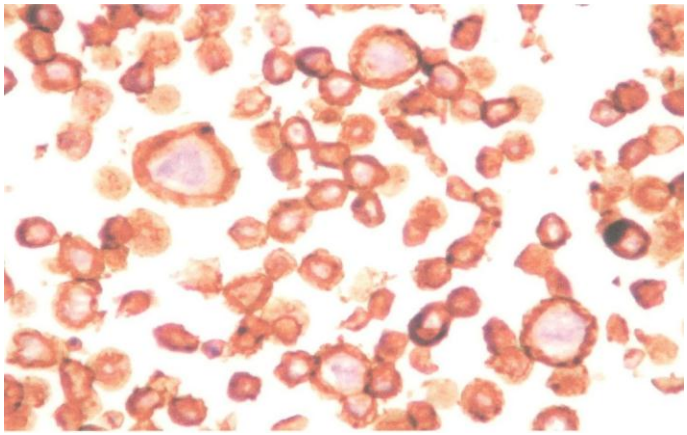

Figure 3. Pozitiv +3
External positive control mammary cell lines

Interpretation of results

In interpreting the results, it was considered only the end product of membrane localized reaction. They were excluded from interpretation reaction cases had diffuse cytoplasmic membrane without enhancement (n = 2).

The positive control was the lame external test kit included in Hercep Test, represented by malignant breast cell lines, denoted by 0, +1 and +3 provided by the manufacturer.

RESULTS

Overexpression of HER-2 / neu is well known in colorectal adenocarcinomas and therefore cases with malignant tumors were positive reaction control method for assessing the conditions of UC. The reaction was positive in 3 of the 4 cases of adenocarcinoma. The end product of the reaction, and the cytoplasmic membrane was located after the above model for the external positive control (Figures 4 and 5).

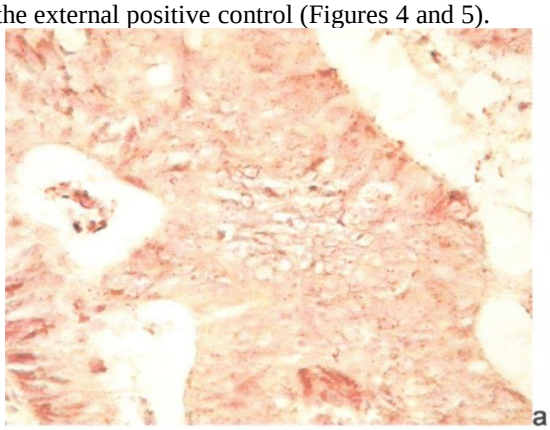

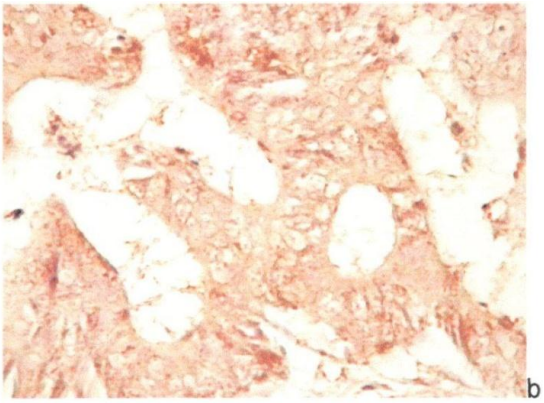

Figure 4. Membrane

Figure 5. Cytoplasmic

External positive control for adenocarcinoma

Normal rectal mucosa and inactive forms of UC were negative for all cases included in the study. (Figure 6) of cases with active UC, 7 were positive, both membrane and cytoplasmic level. Have they excluded all cases with type 1 reaction,

as negative. The intensity of the final product of the reaction was low compared with adenocarcinoma, but it is worth noting that stained both surface epithelial cells, and the glands. (Figure 7)

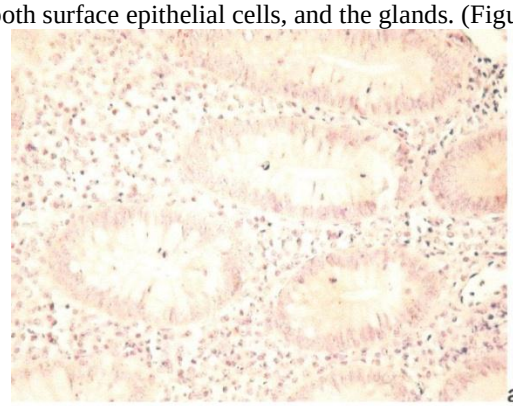

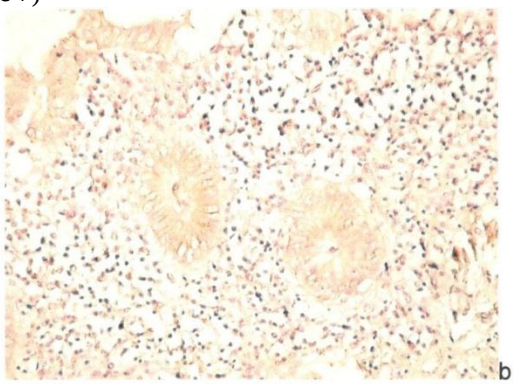

Figure 6. Normal rectal mucosa Figure 7. Active UC

The reaction was more intense in presenting pseudostratificari epithelial glands and the preparations stained routine that I noticed numerous mitotic figures (Figure 8). The cases were characterized by marked proliferative activity, demonstrated by high index PCNA and Ki67 in immunoreacted for.

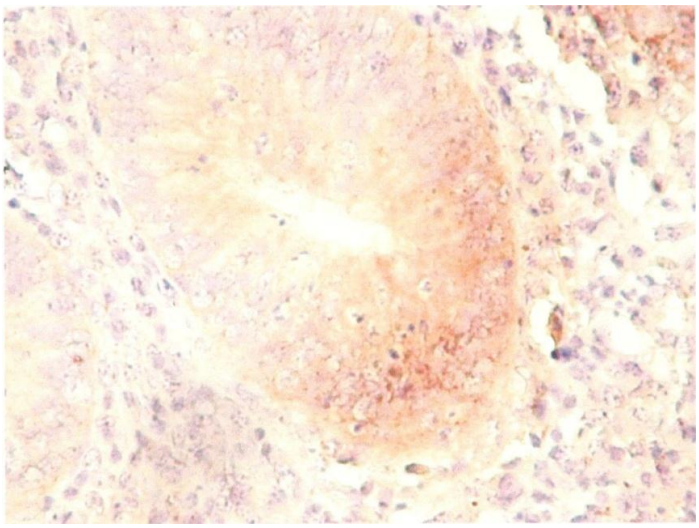

Figure 8. Intense immunoreaction +3

These cases were positive immunoreactive entire length glands, chair if they have not shown significant morphological changes (Figure 9).

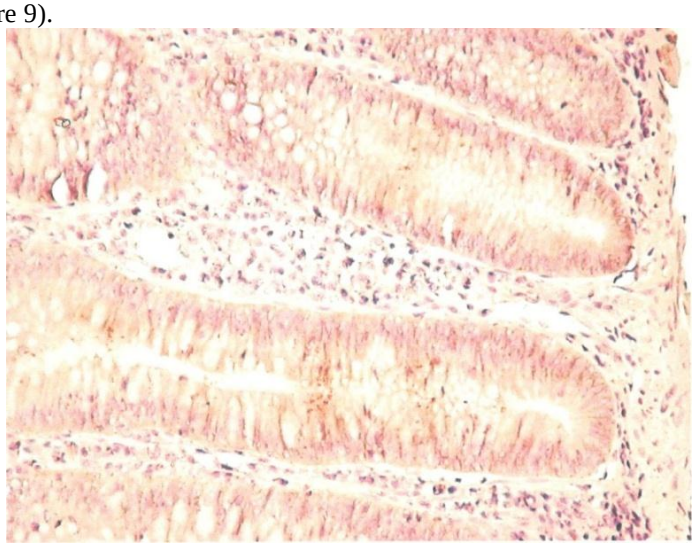

Figure 9. Positive immunoreation for HER-2/neu in active UC

© 2015 Vasile Goldis University Press (www.jmedar.ro)

In light of these observations that overexpression of HER believe-2 / neu expression can be considered glandular proliferative capacity of the cells. For lesions of other sites overexpression HER-2 / neu is a risk factor for malignant transformation and tumor progression. Regarding colorectal lesions there are currently no reasons for this.

Corroboration of HER-2 expression index PCNA and Ki67 increased to reflect the potential proliferative glandular cells, which attract a certain protocol monitoring these patients. From this point of view we conclude that overexpression of HER-2 is a prognostic factor in patients with active UC individual.

REFERENCES

Sternberg S.S, Histology for pathologists, Raven-Lippicot 2002

Grigorescu M, Pascu O, Gastroenerology Treaty, Ed. Tehnica 1996

Cozma F, Research Reguarding The Cancer Risk in Ulcerative Colitis, PhD thesis 2003

Laurent Beaugerie, M.D., Ph.D., and Steven H. Itzkowitz, M.D. Cancers Complicating Inflammatory Bowel Disease N Engl J Med 2015; 372:1441-1452April 9, 2015DOI: 10.1056/NEJMra1403718

Corespondent Carmen Neamtu
Str.Gradinarilor nr 43
e-mail carmen.neamtu@gmail.com
telefon 0040723225793